

**INCLUSION BODY  
HEPATITIS AND  
HYDROPERICARDIUM  
SYNDROME  
(ADENOVIRUS INFECTIONS)**

**Dr. J.L. VEGAD  
PhD (New Zealand),  
Visiting Professor  
(USA), FIAVP, FNAVS**

# **AVIAN ADENOVIRUSES (CHICKEN ADENOVIRUSES, FADV)**

**Adenoviruses are common in poultry. Many replicate in healthy birds without showing any clinical signs. Chicken adenoviruses have five species. These are based on molecular criteria (genome). These five genotypes are now regarded as separate adenovirus species. Each species has several serotypes/strains.**

# **DIFFERENT SPECIES (GENOTYPES) AND SEROTYPES OF AVIAN ADENOVIRUSES**

## **Fowl Adenovirus A**

**Serotypes: Fowl adenovirus 1 (FAdV-1)**

## **Fowl Adenovirus B**

**Serotypes: Fowl adenovirus 5 (FAdV-5)**

## **Fowl Adenovirus C**

**Serotypes: Fowl adenovirus 4 (FAdV-4)**

**Fowl adenovirus 10 (FAdV-10)**

## Fowl Adenovirus D

### Serotypes:

Fowl adenovirus 2 (FAdV-2)

Fowl adenovirus 3 (FAdV-3)

Fowl adenovirus 9 (FAdV-9)

Fowl adenovirus 11 (FAdV-11)

## Fowl Adenovirus E

### Serotypes:

Fowl adenovirus 6 (FAdV-6)

Fowl adenovirus 7 (FAdV-7)

Fowl adenovirus 8a (FAdV-8a)

Fowl adenovirus 8b (FAdV-8b)

There are 12 recognized serotypes in the five genotypes.

## **DISEASES CAUSED BY VARIOUS SPECIES**

**Species A**      **causes**      **Gizzard erosions**

**Species B**      **causes**      **No significant disease**

**Species C**      **causes**      **Hydropericardium  
syndrome**

**Species D  
and E**      **cause**      **Inclusion Body Hepatitis**

**Chickens of all ages are susceptible.**

## CAUSE

**Virus has double-stranded DNA. Replication takes place in the nucleus.**

**Virus is resistant to pH between 3 and 9. It is more heat resistant.**

**Some survive 60°C and even up to 70°C for 30 minutes.**

**But 1:1000 concentration of formaldehyde kills the virus.**

## **TRANSMISSION**

Vertical Transmission: Is important in the spread and duration of disease.

Viral antigens are detected in egg yolk and albumen, but adenovirus infection can remain latent and undetected for one generation.

Two or even three strains can infect one bird.  
This suggests little cross protection, despite the presence of high levels of neutralizing antibody to a single serotype.

Chickens infected with adenoviruses are potential carriers for life.

**There is a second period, around peak egg production.**

**The stress of egg production or the increased levels of sex hormone may cause re-activation of the virus.**

**This ensures maximum egg transmission to the next generation.**



# Horizontal Transmission

**This is also important.**

**Virus is present in faeces, tracheal and nasal mucosa, and kidneys. Thus virus is transmitted in all excretions but highest concentration is in the faeces.**

**Semen – potential risk for AI. Spread within a flock is by direct faecal contact. Spread by air over short distances is at a very slow rate for several weeks. Air spread between farms is not of much importance.**

**People, transport, and fomites (eggs, trays, trolley) spread the infection.**

## CLINICAL SIGNS

IBH is characterized by sudden onset of mortality. Peaks after 3-4 days. May continue for 2-3 weeks. Morbidity is low. Sick birds adopt a crouching position with ruffled feathers and die within 48 hours or recover. Mortality may be 10%, and sometimes 30%. IBH is mostly seen in broilers. It may be seen in birds as young as 7 days.

Sometimes no clinical signs are seen, but on postmortem there is degeneration and necrosis in the liver.

**Many different serotypes have been associated with outbreaks of IBH.**

**They belong mainly to D or E species in which serotypes 2, 3, 6, 7, 8a, 8b, 11 are combined.**

**Immunosuppression caused by IBDV infection helps adenoviruses in producing IBH.**

**Also, if birds are infected with both CIA and adenovirus, there is increased incidence of hepatitis and death.**

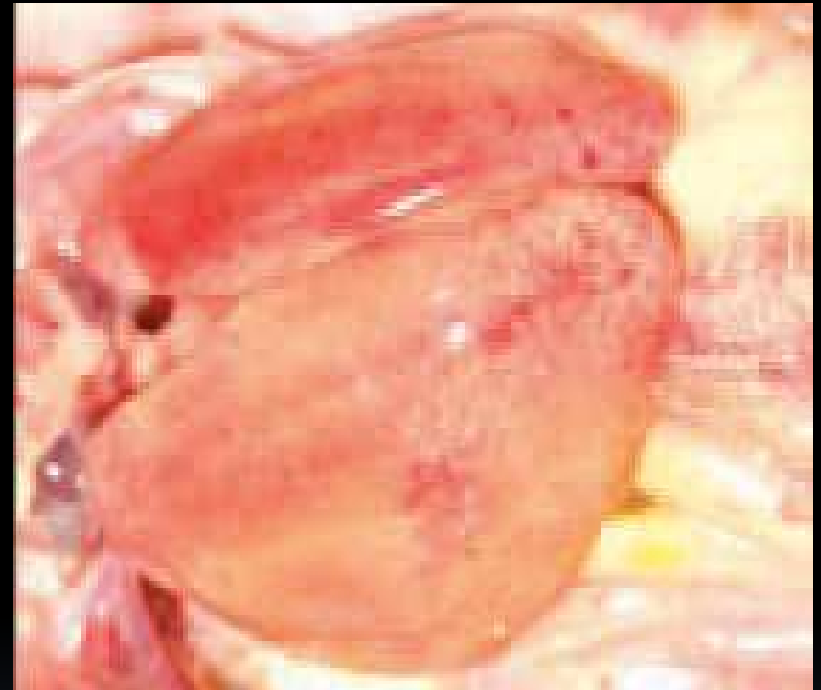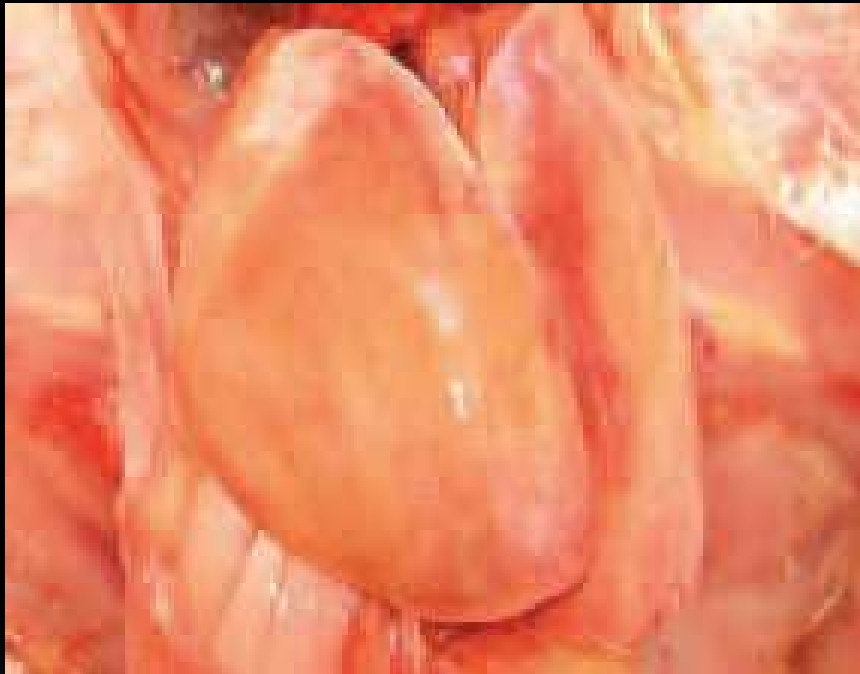**IBH in India is often associated with aflatoxin in the feed, but the primary cause is FAdV.**

# POSTMORTEM LESIONS

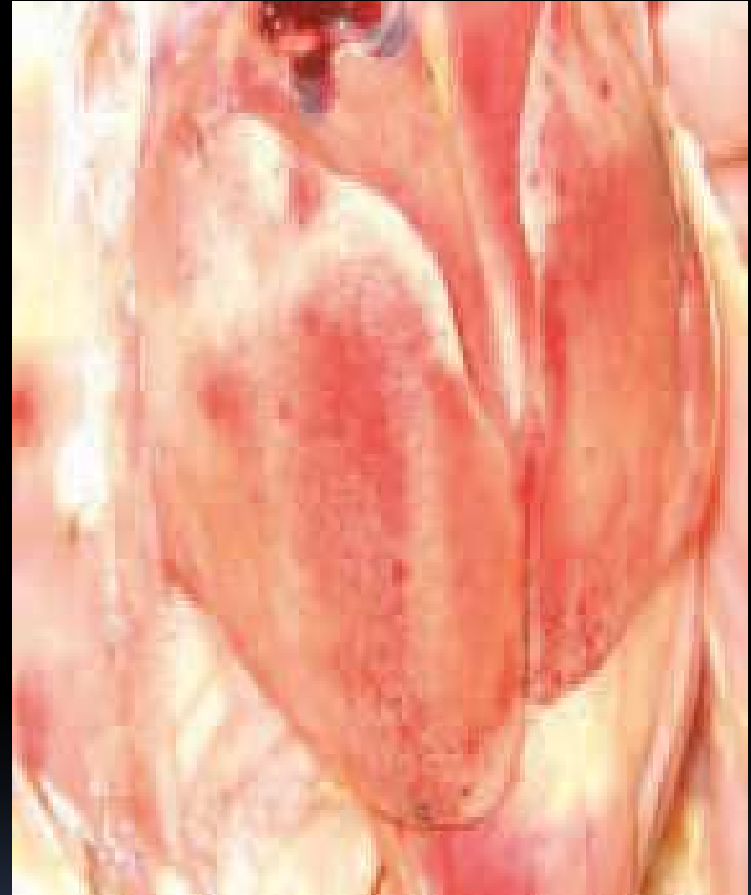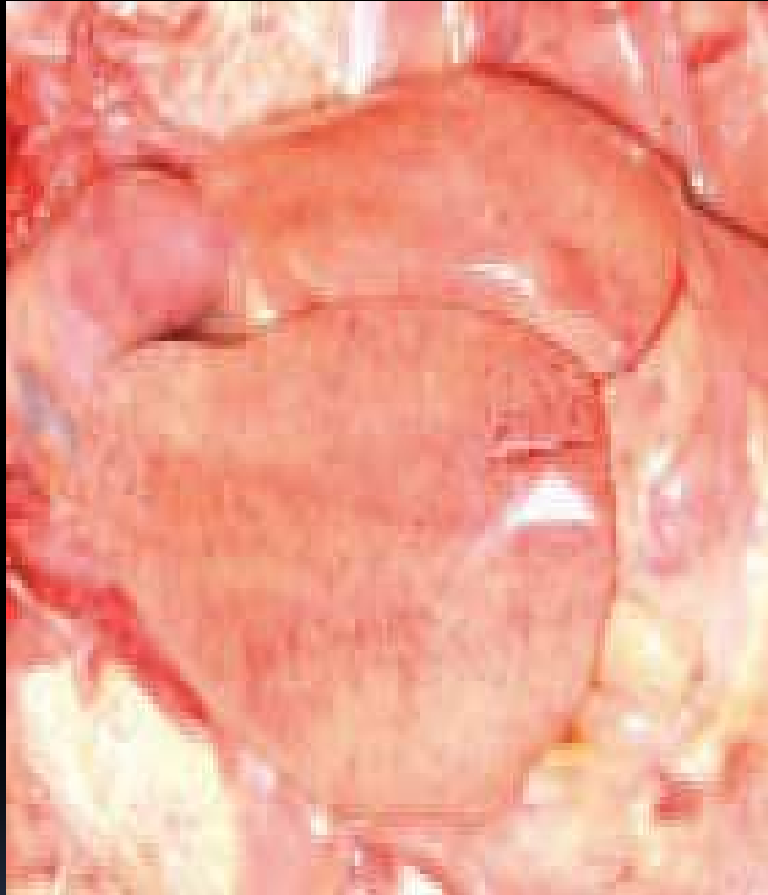
## Gross

Livers are pale, friable and swollen and may show small white foci of necrosis on the surface.

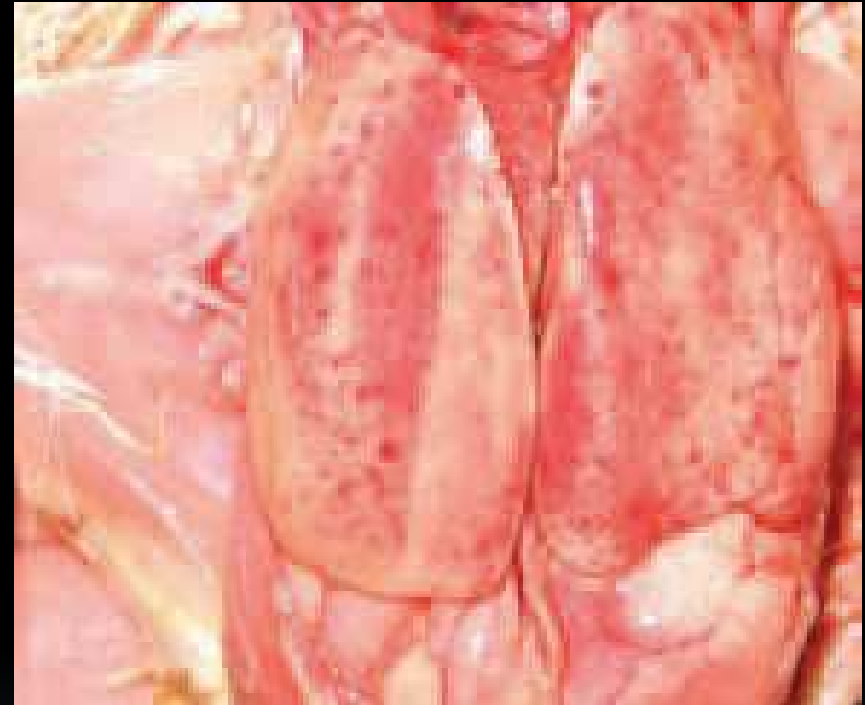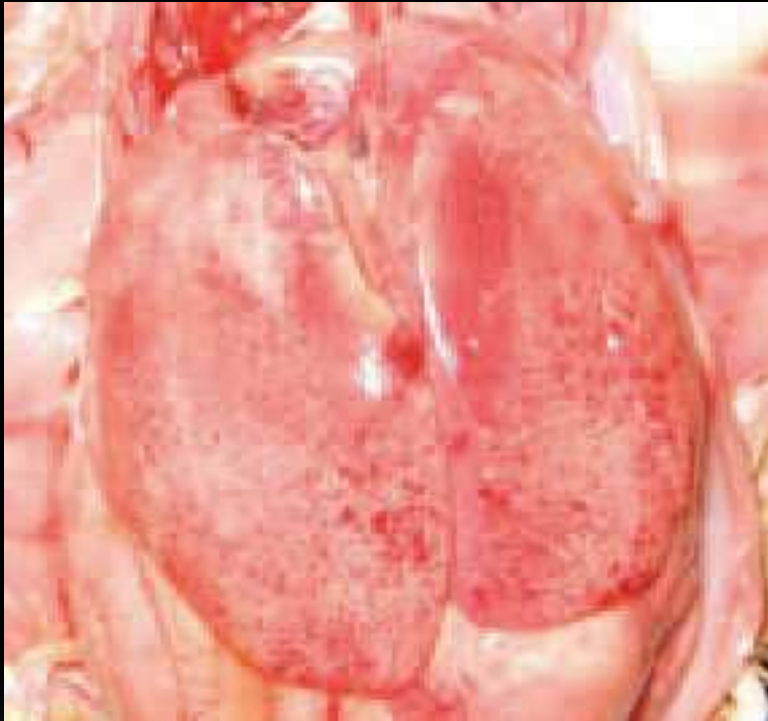
Petechial and ecchymotic haemorrhages are seen on the liver and skeletal muscles.



Livers are pale , friable and swollen

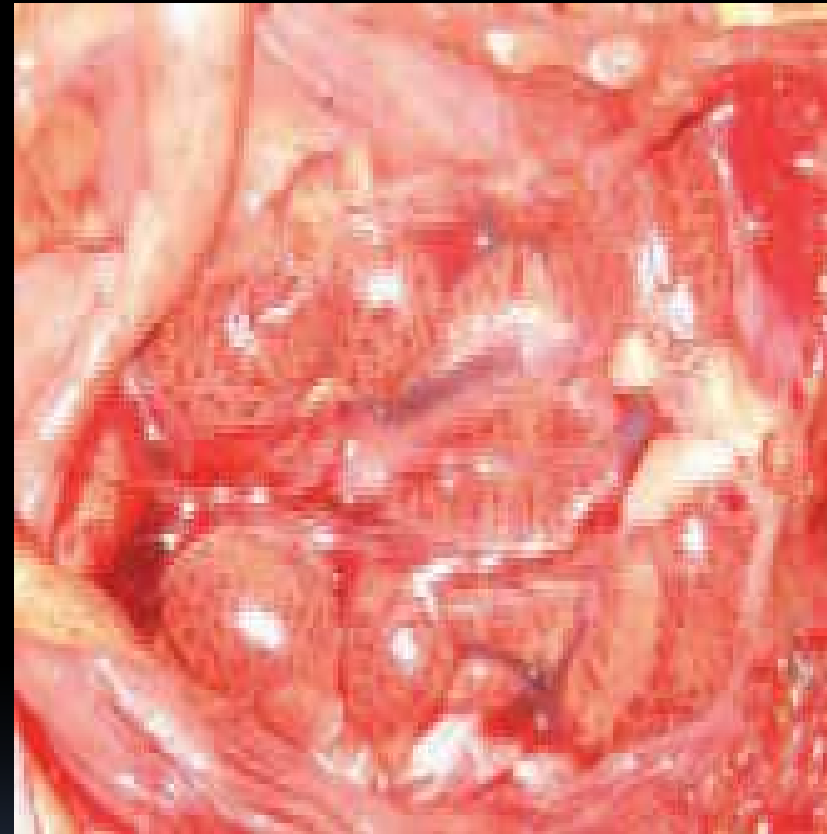
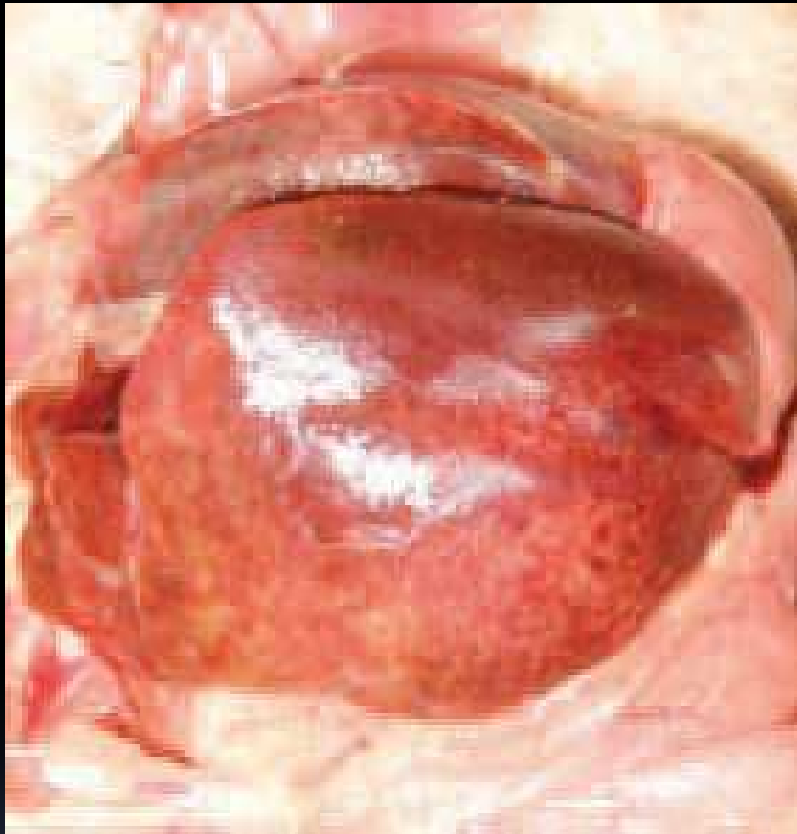
Livers are pale , friable and swollen

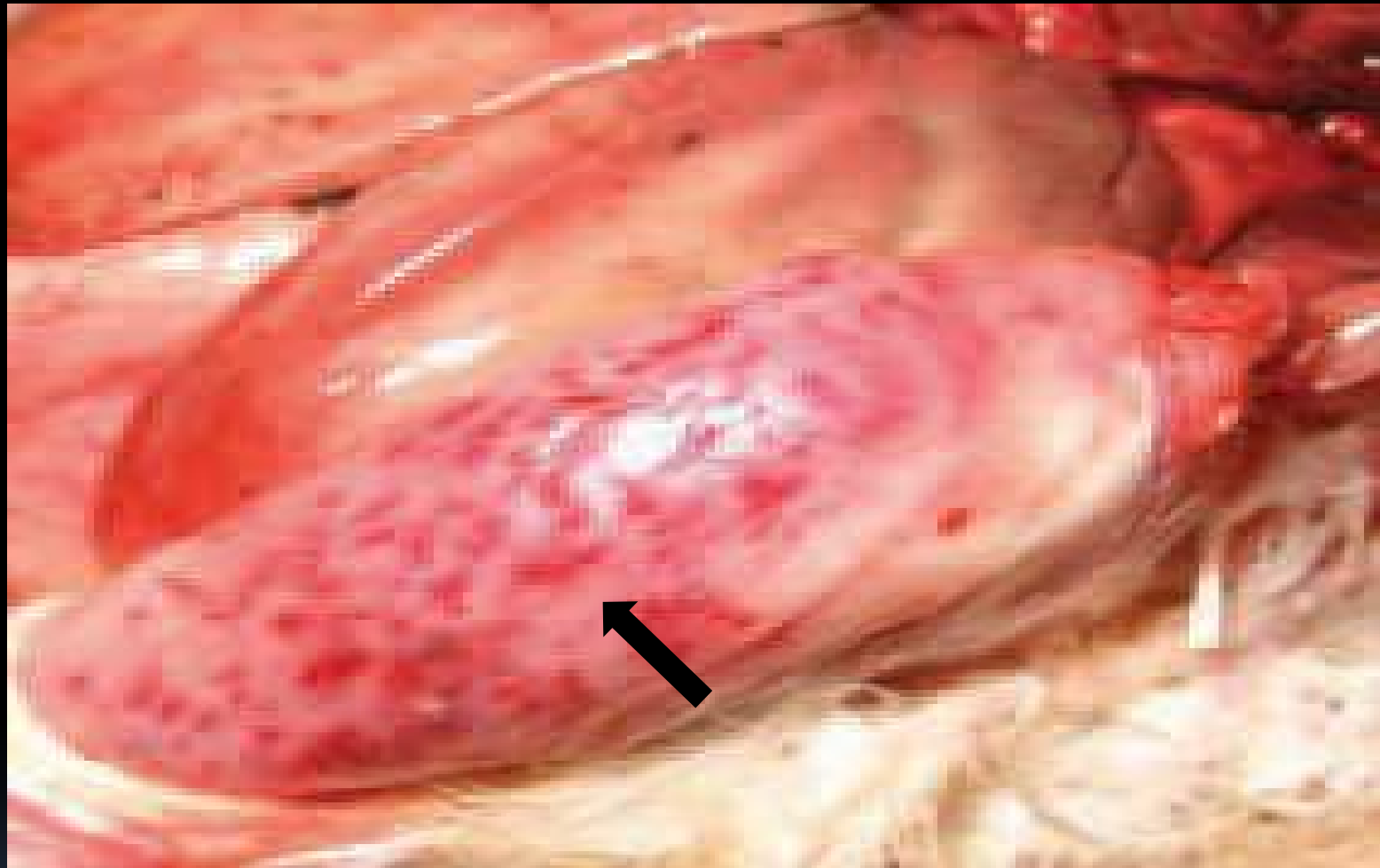


Livers from broilers of 3- 8 weeks showing characteristic haemorrhages of various intensity and size





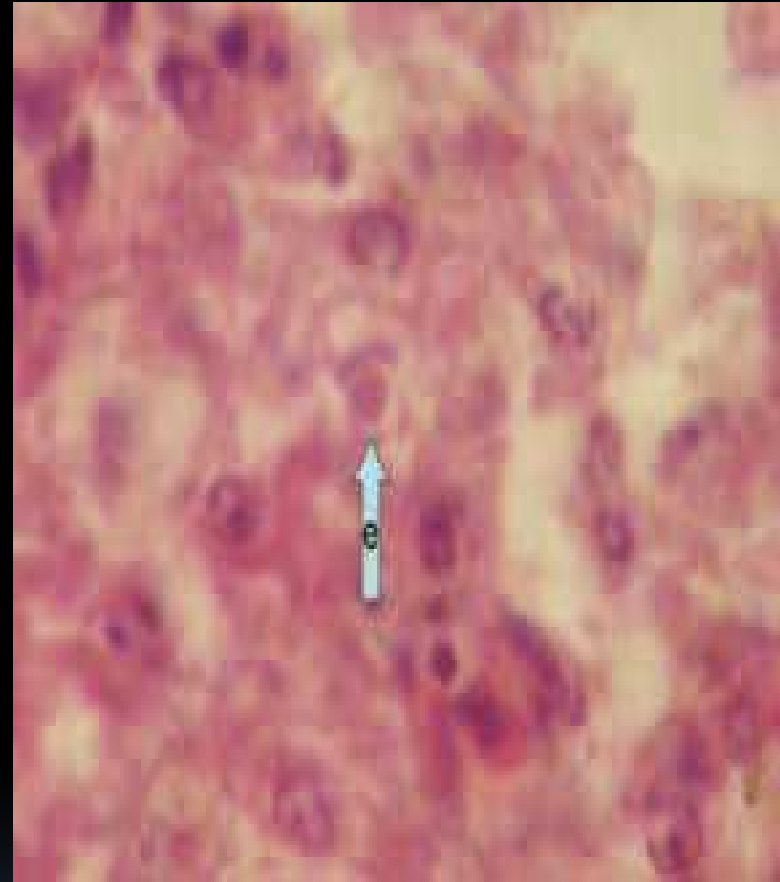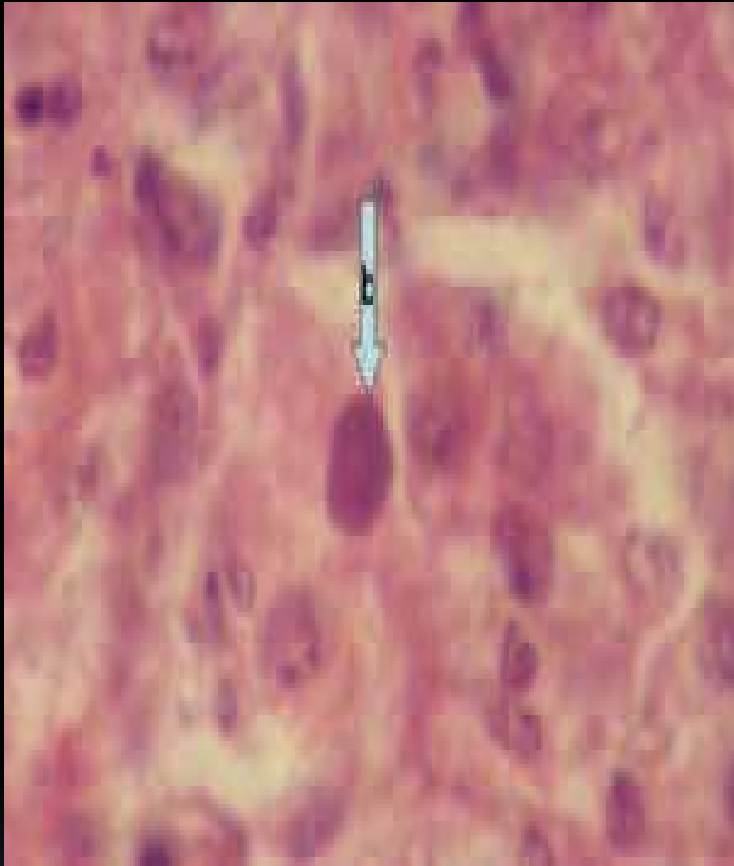
Liver on the left is swollen, shows haemorrhages and small white foci of necrosis . Kidney on the right is swollen and shows haemorrhages.



Note bigger hemorrhages on thigh muscles (arrow).  
In the background is liver.

**Microscopically, inclusion bodies are seen in liver cells. These can be eosinophilic, large, round, or irregular with a clear pale halo, or sometimes basophilic.**

**Only basophilic inclusions contain viral particles, eosinophilic inclusions are composed of a fibrillar granular material. Other lesions include atrophy of bursa and thymus.**



Liver cells show basophilic and eosinophilic inclusion bodies. Basophilic inclusion bodies on the left are dense and occupy the entire nucleus, whereas the eosinophilic are round and surrounded by a light halo.

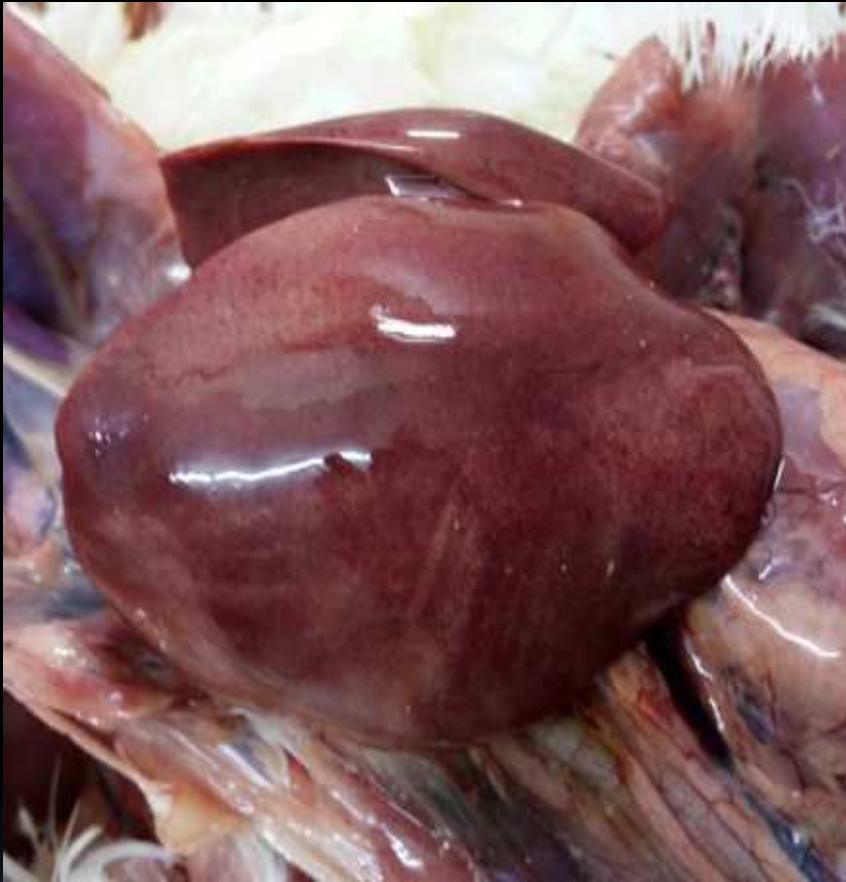## **HYDROPERICARDIUM SYNDROME (HS)**

**Close relationship exists between IBH and HS. Disease is known as “Hepatitis-hydropericardium syndrome”.**

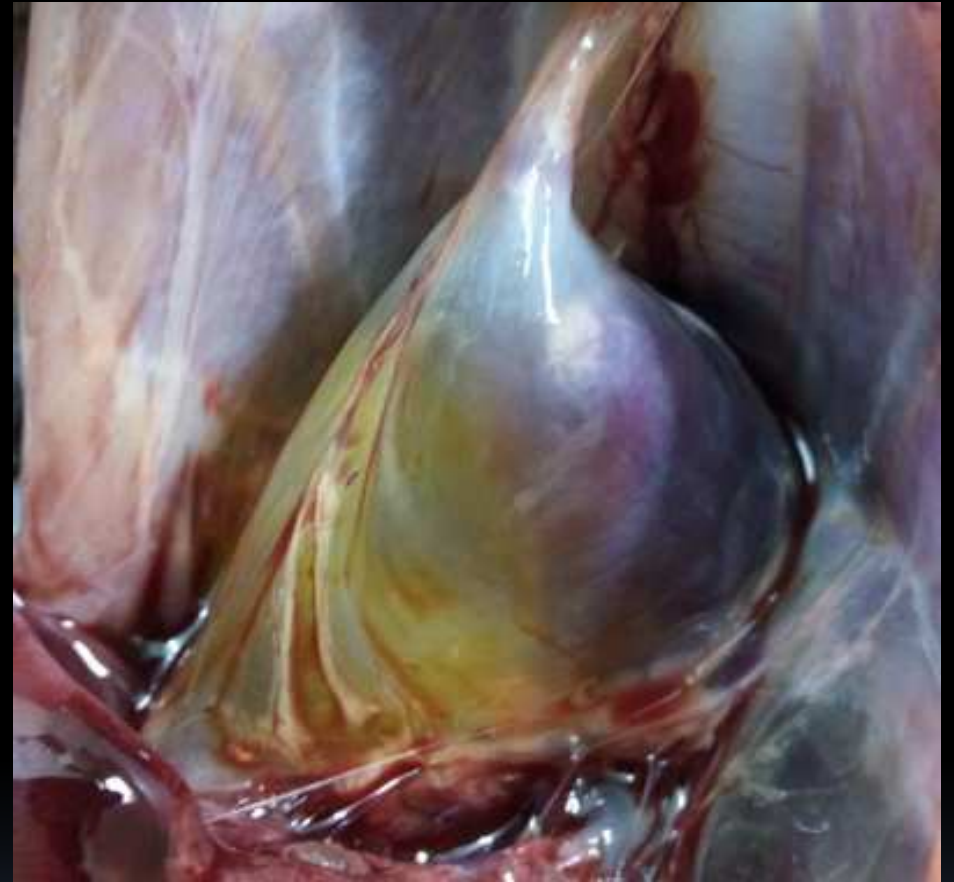**HS is caused by FAdV – C virus serotype 4, whereas IBH is caused by FAdV – D and E.**

**In India, in D species serotype 12 has been detected.**

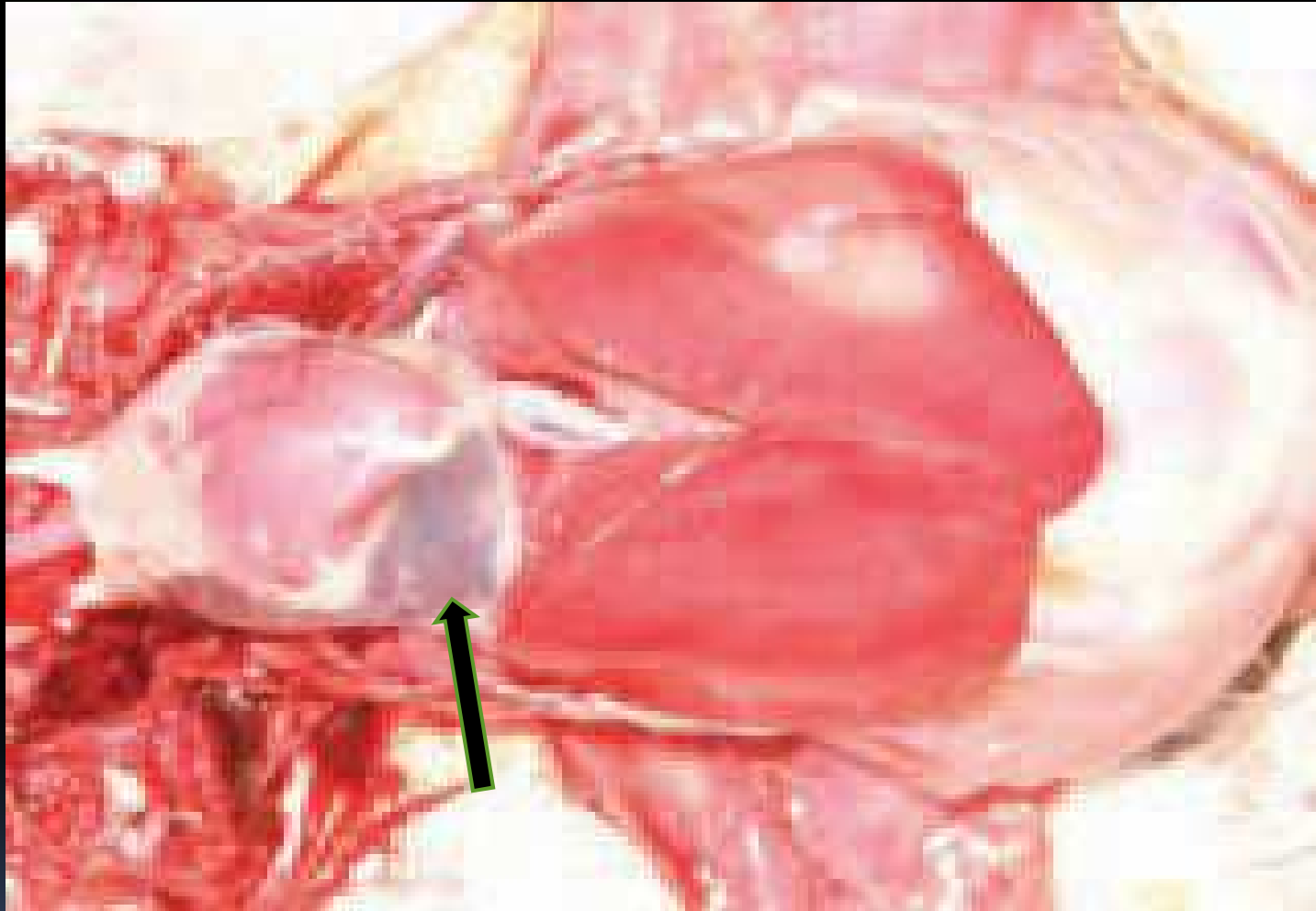
**This virus also spreads vertically and horizontally.**



Liver is swollen, shows haemorrhages and small white foci of necrosis



Hydropericardium.



In many cases of IBH the amount of pericardial fluid is increased (hydropericardium, see arrow).

## POSTMORTEM LESIONS

Accumulation of clear, straw-coloured fluid in the pericardial sac; lung oedema; swollen and discoloured livers.

Kidneys are enlarged and show petechial haemorrhages.

Petechial haemorrhages and areas of focal necrosis are also present in the heart and liver.

Basophilic inclusions are present in the liver cells.



# DIAGNOSIS

ELISA test is good for the detection of group-specific antibodies.

Serum neutralization test is used to detect type-specific antibodies.

But the presence of multiple serotypes complicates interpretation.

Presence of humoral antibodies gives no indication of the state of local immunity at mucosal surfaces.

# IMMUNITY

**Aviadenoviruses have common group-specific antigen.**

**Following infection, neutralizing antibodies produced are type-specific.**

**These are detected after one week and reach peak titres at 3 weeks.**

**Birds are resistant to re-infection up to 45 days with the same serotype.**

**Birds can get re-infected with the same strain after 8 weeks.**

**Virus excretion also occurs despite the presence of humoral antibodies.**

## Immunity Continued

Local immunity is short-lived and lasts about 8 weeks. It resists the infection, whereas circulating antibodies protect mainly against invasion of internal organs.

The correlation between appearance of circulating antibodies and stoppage of virus excretion is due to concurrent development of both local immunity, which is short-lived, and humoral immunity, which is more persistent.

**Maternal antibodies do not protect  
against natural routes of infection but  
protects against intra-abdominal  
infection.**

**Regarding protection, neutralizing  
antibodies are not solely responsible.**

## **PREVENTION AND CONTROL**

**1. Aviadenoviruses are resistant to inactivation. To prevent vertical transmission, vaccinate breeders at 10 and 17 weeks with a killed vaccine containing isolates of species D and E.**

**2. An autogenous vaccine prepared by inactivating homogenates of liver has been used in Pakistan and works.**

**There is increased protection of progeny against HS by vaccinating against both chicken infectious anaemia and species FAdV4.**

**This gives increased protection compared to lesser protection achieved by vaccinating birds against either disease alone.**

# CONCLUSIONS

1. There are five species of adenoviruses and 12 serotypes. Each species behaves like a separate virus and there is no cross immunity among species and the serotypes. Cross-infection can occur with several serotypes.
2. Species D and E cause IBH, and species C cause hydropericardium syndrome. There is a close relationship between the two, the disease is then called "Hepatitis-hydropericardium syndrome."

**3. Immunosuppressive diseases, like infectious bursal disease (IBH) and chicken infectious anaemia, help adenovirus to produce IBH.**

**When birds are infected with both, there is increased incidence of inclusion body hepatitis and death. Therefore, these diseases must be controlled with proper and timely vaccination.**



**4. Protection can be obtained by using a killed vaccine but it is serotype specific. Birds are resistant to re-infection against the same serotype up to 45 days. Autogenous vaccine works.**

**5. As the virus is tough and extremely common, strict biosecurity at the farm must be observed at all times.**

Thank you

